

TEMPORARY CROWN RESTORATIONS

Second Edition

Produced by

**QUERCUS CORPORATION
2768 Pineridge Road
Castro Valley, CA 94546**

Copyright 1979

**Department of Health, Education and Welfare
Contract No. 299-74-0016**

Updated Version and Module 5

By

**LUANN SPAIN, C.D.A.
1991**

Revised June 2005

By

Terrie Beckman, CDA, BSEd

Adopted by

**Idaho State Board for Vocational Education
650 West State Street
Boise, Idaho**

TABLE OF CONTENTS

| | |
|--|-----------|
| COURSE OBJECTIVES..... | 5 |
| MODULE 1 – INTRODUCTION TO THE COURSE | |
| INTRODUCTION..... | 6 |
| BACKGROUND INFORMATION..... | 7 |
| TYPES OF TEMPORARY CROWNS..... | 10 |
| Anatomical Metal Crowns..... | |
| Preformed Plastic Crowns..... | |
| Custom Resin Crowns..... | |
| Finish Lines..... | |
| Resin Materials..... | |
| Methyl Methacrylate..... | |
| Light-Cure Resin..... | |
| Ethyl or Vinyl Ethyl Methacrylates..... | |
| Epimines..... | |
| Composites..... | |
| OCCLUSION..... | 14 |
| TEMPORARY CEMENT..... | 15 |
| PLACING TEMPORARY CROWNS..... | 15 |
| ASEPTIC TECHNIQUE..... | 17 |
| MODULE 2 – PLACING A PREFORMED ALUMINUM TEMPORARY CROWN | |
| TEMPORARY CROWNS..... | 19 |
| Overview of Procedure..... | 20 |
| ARMAMENTARIUM..... | 21 |

| | |
|--|-----------|
| PROCEDURE..... | 22 |
| Preliminary Procedures | |
| Crown Placement Procedures | |
| SUMMARY OF PROCEDURE AND CRITERIA | 28 |
| MODULE 3 - PLACING A PREFORMED PLASTIC TEMPORARY CROWN | |
| PLACING A PREFORMED POLYCARBONATE TEMPORARY | |
| CROWN | 30 |
| Overview of Procedure | 31 |
| ARMAMENTARIUM | 33 |
| PROCEDURES | 34 |
| Preliminary Procedures | |
| Crown Placement Procedure | |
| SUMMARY OF PROCEDURE AND CRITERIA | 43 |
| MODULE 4 - PLACING A CUSTOM PLASTIC TEMPORARY CROWN | |
| PLACING A CUSTOM RESIN TEMPORARY CROWN | 46 |
| Overview of Procedure | 47 |
| ARMAMENTARIUM | 48 |
| PROCEDURE | 49 |
| Preliminary Procedure | |
| Crown Fabrication and Placement Procedures | |
| SUMMARY OF PROCEDURES AND CRITERIA | 54 |
| MODULE 5 – ADDITIONAL TECHNIQUES EMPLOYED FOR FABRICATION OF CUSTOM | |
| TEMPORARY CROWNS..... | 56 |
| STUDY QUESTIONS..... | 60 |
| REFERENCES | 62 |

FIGURES

| | | |
|-----|--|----|
| 1. | COMMONLY USED FINISH LINES | 7 |
| 3. | TOOTH-TO-TOOTH CENTRIC CONTACT..... | 14 |
| 4. | PATTERN OF OCCLUSAL MARKINGS..... | 14 |
| 5. | IDEAL PATTERNS OF OCCLUSAL MARKINGS..... | 14 |
| 6. | MESIAL VIEW OF TOOTH #18 | 14 |
| 7. | FACIAL VIEW OF TOOTH #18..... | 22 |
| 8. | LINGUAL VIEW OF TOOTH #18 | 22 |
| 9. | OCCLUSAL VIEW OF TOOTH NUMBER #18 | 22 |
| 13. | FACIAL/MESIAL VIEWS OF TOOTH #8..... | 43 |

Objectives

Following completion of lecture and laboratory activities, the student will be able to :

1. Explain why temporary crown restorations are placed.
2. List and describe the types of temporary crowns, their advantages and disadvantages.
3. List and explain the types of finish line forms.
4. Describe types of resin materials and their advantages, disadvantages, and demonstrate proper mixing technique.
5. Describe the procedures of each type of temporary crown.
6. Fabricate a crown from each module according to the stated criteria.
7. Define and explain the importance of correct occlusion.
8. Demonstrate the ability to correctly evaluate each crown placement that meet and do not meet the criteria for restorations of these preparations.
9. List and describe additional techniques that are employed for fabrication of custom crowns.
10. Explain the advantages of the updated techniques for custom temporary crowns.
11. Define the purpose of temporary cement.
12. Explain aseptic techniques as it applies to these modules.

Module 1
Introduction to the course

TEMPORARY CROWN RESTORATIONS

INTRODUCTION

The Project ACCORDE Temporary Crown Restorations consists of three modules, “Preformed Metal Crowns,” “Preformed Metal Crowns,” Preformed Plastic Crowns,” and “Custom Resin Crowns.” For additional reference, the supplemental module “Additional Techniques Employed for Fabrication of Custom Temporary Crowns” has been included in the Project Accorde module. It is essential that you read the background information, a description of procedures and criteria, and review the evaluation form.

The procedure description will provide step-by-step instructions for each procedure involved in the temporary crown restoration. Procedures outlined in the modules are designed specifically for the learning situation, with an emphasis on introducing new concepts and skills. It should be understood that procedures and techniques may vary with each dental office. Only a limited amount of experience can be gained in a lab situation, so it is suggested that students seek additional experience in the dental office.

Evaluation is a vital element of this course and it is the responsibility of both the student and the instructor. Your ability to evaluate your own work, according to the criteria, will help you gain an even better understanding of the proper techniques and procedures. In a dental situation, the quality of your temporary crowns will depend largely on your ability to self-assess your work. The instructor’s evaluation will guide you in the application of the accepted criteria and in the development of your skills.

Tests are an important part of the evaluation process. They check your knowledge of the technical background information and your ability to apply both knowledge and skill to similar but different temporary crown restorations. Your instruction will test you on the different temporary crowns, after competence has been gained in all areas.

BACKGROUND INFORMATION

When the pathology of a tooth is such that a cavity preparation and amalgam or a tooth-colored restoration are considered inadequate to restore the tooth to its original form and function- that is, if the tooth is badly decayed, brittle as a result of endodontic treatment, losing function, or unaesthetic- one satisfactory restorative method is the application of a crown. Crowns are also used to cover undamaged teeth when bridge abutments are required.

From the standpoint of the patient's oral health, the care and placement of temporary crowns is essential for the following reasons:

1. **TO PREVENT SENSITIVITY IN THE PREPARED TOOTH.**

During crown preparation, portions of the teeth's enamel and dentin are removed. Dentin contains microscopic tubules that originate in the pulp and terminate at the dento-enamel junction. As the dentin is prepared, the tubules are severed and left open, leaving the highly sensitive pulp of the tooth exposed. It is important not to desiccate the preparation because of the sensitivity that occurs with the tubules severed. Because the tubules are open, it is necessary to consider the chemical composition of the material that is placed adjacent to the dentin. If potentially irritating substances must be used, dentin can be protected by coating the surface of the preparation with a substance that seals the tubules.

2. **TO PROTECT THE DENTIN FROM ORAL FLUIDS.**

Oral fluids may cause sensitivity.

3. **TO MAINTAIN OCCLUSION.**

To prevent supra-eruption of the prepared tooth or the opposing tooth, and to prevent movement of the prepared tooth or the adjacent teeth.

The contact of the mandibular teeth against the opposing maxillary teeth during functional and non-functional movement of the mandible is called occlusion. Occlusion will be discussed in more detail later in this module.

4. **TO PREVENT FRACTURING OF THE FINISH LINE OR BREAKDOWN OF THE PREPARED TOOTH.**

Emphasis is given to the finish line of the preparation, commonly stated as the place where the bur stops. The finish line is a continuous edge that borders the entire preparation. It is essential that you have a mental image of the location and contour of a preparation's finish line in order to contour a temporary restoration for that tooth. (Shown later are various forms of finish lines.)

5. **TO PREVENT CHANGES IN GINGIVAL TISSUE, CAUSED BY INFRINGEMENT OF THE CROWN MARGIN ON THE FREE GINGIVA OR BY FOOD IMPACTION.**

Since most clinical crown preparations present subgingival finish lines, crown margin contour is critical to the health of the gingiva. Should the crown intrude on the gingiva, irritation will result, causing the patient discomfort. Recession, inflammation, ulceration, and infection of the gingiva are possibilities.

Food impaction is likely to occur if the walls of a crown are not properly contoured to reproduce normal anatomy or its contacts with adjacent teeth are not adequately established. Firm contacts normally exist between teeth (in the middle third for posterior teeth and in the incisal third for anterior teeth), which force food to be broken down into two parts and distributed down the facial and lingual surfaces of the teeth. If there is no contact, biting pressure forces food between the teeth and gingiva. The food can cause irritation, which may lead to inflammation and infection.

6. **TO PROVIDE FOR LOST FUNCTION.**

A temporary crown may be placed to protect a chipped tooth and to restore ideal occlusion and surface anatomy.

7. **TO MAINTAIN AESTHETICS**

This is especially important in the anterior permanent teeth.

8. **TO RESTORE OR IMPROVE THE CONTOUR OF THE ORIGINAL TOOTH.**

An example would be a chipped incisal edge.

TYPES OF TEMPORARY CROWNS

Several types of temporary crowns and crown material are available. Those that are commercially available are: preformed anatomical metal crowns, non-anatomical metal crowns, preformed polycarbonate crowns. Cellulose crown forms, as well as synthetic resin the operator can use to fabricate custom resin crowns.

Anatomical Metal Crowns

The term “anatomical” refers to crown forms whose exteriors approximate natural teeth in facial, lingual, mesial and distal contours, as well as in the contours of the occlusal surfaces (cusps, ridges, pits, and grooves).

1. **The Stainless Steel Crown** is used the most durable of the preformed anatomical crowns, which is used most often in restoring primary teeth. Such a crown can provide temporary coverage for months or years. The short comings of the stainless steel crown include its poor aesthetic quality for placing on an anterior tooth and the difficulty of adapting its rigid metal margin to the tooth preparation.
2. **An “Anodized” Aluminum Crown** is used most commonly on premolars and molars because of their resistance to wear, strength and unaesthetic appearance. The chief advantage of this crown is its malleability, which allows for good occlusal adjustment. Tin, silver alloy crowns are the softest and most ductile crowns commercially available for the temporary coverage of posterior permanent teeth. The softness of the alloy eases marginal and occlusal adaptation, as the material will stretch up to 50%. It can also be contoured and burnished without wrinkling. Softness, however, is the chief disadvantage of this crown. It can easily wear through during normal mastication; hence, is recommended for a short time, unless it can again be re-lined with acrylic resin for added strength.

Preformed Plastic Crowns

These crowns are used as temporary coverage for anterior teeth. The advantage of these crowns from the patient’s point of view is that they are tooth-colored making them aesthetically pleasing replacements. From the operator’s view, they can be made to fit the preparation easily, as it can be shortened by cutting, or lengthened by adding resin. There are only a limited number of shades.

1. **Polycarbonate Preformed Crowns.** These crowns are hollow, tooth-shaped with walls about 0.3 mm thick. Polycarbonate crowns are usually only available in two tooth-colored shades. The operator selects the lighter or darker shade, which ever is closer to the color of the tooth being restored. The polycarbonate-preformed crowns are more commonly used in practice than cellulose crowns.
3. **Cellulose Crown Forms.** This type of crown is a clear, hollow crown form. The advantage to this particular crown is that the operator is able to be more selective cellulose crown form is that when the form is removed from the acrylic resin, the adjacent teeth may be slightly out of contact. However, the operator is able to choose a larger variety of shapes and colors with this type of crown.

Custom Resin Crowns

The custom resin crown is tooth colored and is completely fabricated by the operator. The fit and external contours of the crown are superior to those of any other temporary crown, since it is made in an impression of the patient's mouth. This crown can be adapted to any tooth and is esthetically pleasing. The disadvantage to this crown is that some operators feel it takes longer to produce.

The choice of an appropriate temporary crown depends on which tooth is to be restored, the patient's concern for aesthetics, and the length of time a temporary restoration must serve. With this information, you can make the judgement.

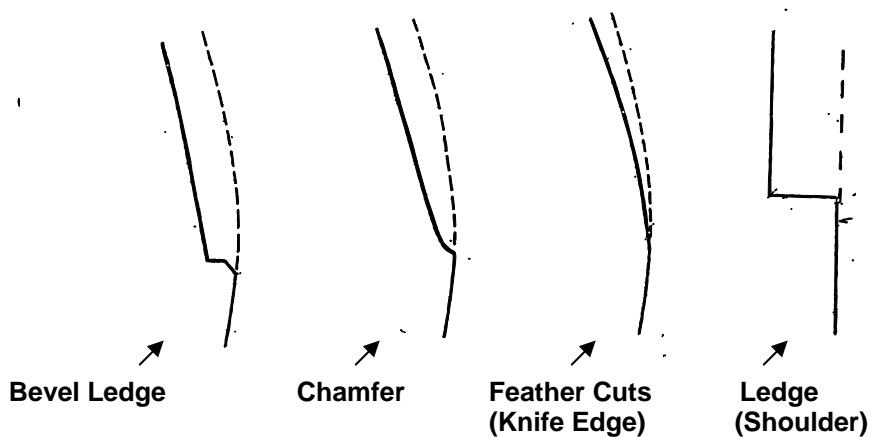
Finish Lines

The finish line is a continuous edge that borders the entire preparation commonly the location where the bur stops. It is essential that you have a mental image of the location and contour of a preparation's finish line in order to contour a temporary restoration for that tooth.

Four common forms of finish lines are:

1. Bevel or slant
2. Chamfer or slope
3. Feather or knife edge (a shallower slope), and
4. Shoulder or ledge

FIGURE 1
COMMONLY USED FINISH LINES



Bevel, chamfer, feather cuts and shoulder (left to right) are used at preparation finish lines.

When a preparation is cut, the circumference of the tooth either increases or remains the same, with the finish line always at the greatest circumference. This shape permits easy placement and removal of a restoration. A chamfer, bevel or shoulder provide somewhat of a shelf which the restoration can “hug”, thus achieving a snug fit of the crown’s margin (the gingival edge). The temporary restoration, when well adapted, protects the finish line from chipping and prevents marginal leakage of mouth fluids and bacteria, which could cause sensitivity and decay of the exposed dentin.

Should a preparation narrow towards the finish line, that area would be an undercut. Such narrowing is an error in preparation that makes placement of the crown impossible and prevents marginal seal and/or full seating. Since a crown is fabricated to fit the largest circumference of a preparation, any area gingival to that largest dimension will not be sealed. Convexities (positive contours) present similar problems and also tend to prevent marginal seal.

Resin Materials

Resin material is used to line the preformed polycarbonate crown, cellulose crown form, or as a liner for aluminum temporary crowns. It is also fabricated to form a custom temporary crown. The commonly used resin is a combination of a polymer (powder) and a monomer (a liquid). It is important that all of the powder used be incorporated into the liquid. There is no exact proportion of monomer to polymer. The more powder there is, the stronger the mix is, but if the mix is too dry (if it has too much powder), it does not flow and, therefore, does not conform to the contours of the preparation. If there is too much liquid, the mix runs out of the crown when it is placed.

While the acrylic resin has some very desirable qualities, it also has some characteristics that require special attention. Because monomer in its pure form is toxic to the tooth, it is extremely important that it be thoroughly incorporated into the mix. When mixed, the polymer and the monomer polymerize (react chemically) and produce heat, in an exothermic reaction. If large amounts of dentin have been removed from a tooth during preparation, the tooth is likely to be sensitive the heat. The gingiva is also heat-sensitive and can become irritated, coat the tissue with Vaseline.

Five major categories for temporary resin materials are:

1. Methyl Methacrylates
2. Ethyl Methacrylates
3. Vinyl Ethyl Methacrylates
4. Epimines
5. Composites

Methyl Methacrylate -“Jet”

Methyl methacrylate is formed by the mixture of a monomer (liquid) and a polymer (powder) which polymerizes (chemically bonds) and hardens into a durable plastic. Various mixing techniques will be explained later.

Methyl methacrylates have an advantage for their excellent color, stability and wear resistance. If it is important to maintain the vertical dimension or if strength is very

important, it is recommended that the temporary crown be fabricated with methyl methacrylate. Unfortunately, this material tends to generate more heat during the polymerization which increases the possibility of pulp irritation when it is in contact with the cavity preparation during fabrication. It will be important to remove the temporary crown during the polymerization period or to apply air from the air/water syringe during this process. The other disadvantage is the extensive setting shrinkage because of the heat that is generated. A common brand name is Jet.

Light-Cure Resin

A new type of methyl methacrylate resin that is not shown on the table is a light-cure resin. This resin material is not self-curing, meaning it does not cure until it is exposed to a visible light. (The visible light is the type of light that is used with composite resin material.) The light-cured resin comes in a monomer and polymer form but because the resin does not cure without light, it allows the operator time for preparation and correction before curing. In cases of temporary inlay and onlay with undercuts, removal of undercuts, removal of undercuts, etc., can be easily performed after extracting the rubber-like resin from the mouth. This particular resin is of very low shrinkage and excellent color stability. The other advantage with the light-cured resin is that it will adapt with the conventional chemical self-cure resin that is of the same methyl methacrylate base. A common brand name for a light-cure material is Unifast LC.

NOTE: There are light-cure resins that do not come in a monomer or polymer form but in a putty-like consistency. They have an excellent ease of use. A common brand name for this typed of light-cure resin is Triad.

Ethyl or Vinyl Ethyl Methacrylates-Trim II, Snap

Ethyl or vinyl ethyl methacrylates have similar clinical properties, except with the color stability; ethyl methacrylates have been found to be less stable. Their decreased color stability may or may not be a disadvantage depending on the length of time the temporary will be in service and its location.

Ethyl and vinyl ethyl methacrylates do generate less heat than the methyl methacrylates, resulting in a decrease in setting shrinkage. They have an advantage over methyl methacrylates because they are easier to use and there is less potential damage to the tissue. Factors that may cause tissue irritation include the intimate contact of free monomer, the heat generated by the setting reaction, and an allergic reaction. Therefore, care should be taken to lightly coat tissues with petroleum jelly to prevent these irritations while the resins are undergoing chemical and thermal reactions.

Epimines-Scutan

Epimines is a combination of base and catalyst, which forms a paste. The epimines generate little heat during polymerization, which creates the least amount of shrinkage of any of the resin materials. The disadvantage of this resin is its poor color stability and wear resistance. Epimine resins do not react with zinc oxide eugenol (ZOE) cement. Therefore, the operator can remove the old ZOE cement from the internal aspect of the temporary crown and re-cement it without experiencing the usual soft, rubbery condition noted when using the methyl or ethyl methacrylates.

Composites-Protemp, Integrity

Another type of material that is not listed on the table is bis-acryl composite. A common brand is Protemp. This material comes in tow-tube form: one of catalyst and one of base. They have high strength, very low heat and shrinkage. The disadvantage with

bis-acryl composite is that it does not have a putty stage and is fairly expensive. Because bis-acryl is a composite resin it will adhere to other composite restorations. For example, composite restorative material can be used to cover voids when the crown does not meet the finish line.

NOTE: Resins can cause tissue irritation (i.e. contact with monomer, heat generated or allergic reactions) so tissue should be coated with vasoline.

OCCLUSION

The contact of the mandibular teeth against the opposing maxillary teeth during functional and non-functional movement of the mandible is called occlusion. The static position of the bite is called centric occlusion.

In the normal adult dentition, the supporting cusps maintain centric stop contacts with opposing fossae and/or ridges and thus maintain the occlusal vertical dimension of the face. In order to maintain a stable centric occlusion, the forces applied to these centric stops should be directed down the long axes of the teeth.

The lingual cusps of the maxillary molars and premolars are supporting cusps that create centric stop contact with the opposing mandibular fossae and/or ridges. The facial buccal cusps of the mandibular molars and premolars are also supporting cusps that contact opposing maxillary fossae and/or ridges.

The maxillary facial buccal cusps have no centric contact. They are positioned with facial horizontal overlap relative to the mandibular facial buccal cusps, and they serve to keep the patient's cheek off the occlusal table.

The mandibular lingual cusps also have no centric contact. They are positioned with lingual horizontal overlap relative to the maxillary lingual cusps, and they serve to keep the patient's tongue off the occlusal table.

From a facial view of the dentofrom's occlusion, you will notice the posterior teeth have a tooth-to-two-teeth centric contact (Figure 3). That is, each posterior mandibular tooth contacts two opposing maxillary teeth, and each posterior maxillary tooth contacts two opposing maxillary teeth. Though there are other theories of occlusion and you will find unlimited variations on patients, this occlusal pattern is described in this course because manikins or dentofoms are typically manufactured with this scheme.

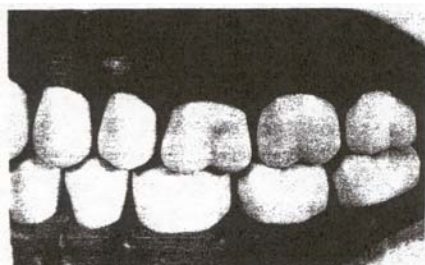
It is expected that the student will have some background in occlusion before beginning the course; therefore, only a functional explanation of occlusal checks is given.

A marking on every tooth except the crown restoration indicates that the restoration is in infra-occlusion, or below the occlusal plane of the adjacent teeth. This could initiate supra-eruption (extrusion beyond the occlusal plane of the adjacent teeth) by the opposing teeth, an irreversible process. The appearance of a marking on the crown alone indicates the crown is in supraocclusion (beyond the occlusal plane of the adjacent teeth) which may cause opposing teeth to intrude into their sockets, thereby weakening and sensitizing them. Another destructive process that can be instigated by improper occlusion is the movement (drift) of teeth that can result when occlusal forces are not directed along the long axis of the teeth. From the operator's point of view, it is important for the temporary crown restorations to maintain a stable occlusal relationship because a prepared tooth without occlusal contact may erupt or shift position within a few days. If this occurs, the permanent crown will be in supraocclusion (too high) or impossible to seat, necessitating the fabrication of another permanent crown. Because of

these possibilities, great attention is given to checking and restoring proper occlusion during temporary crown placement.

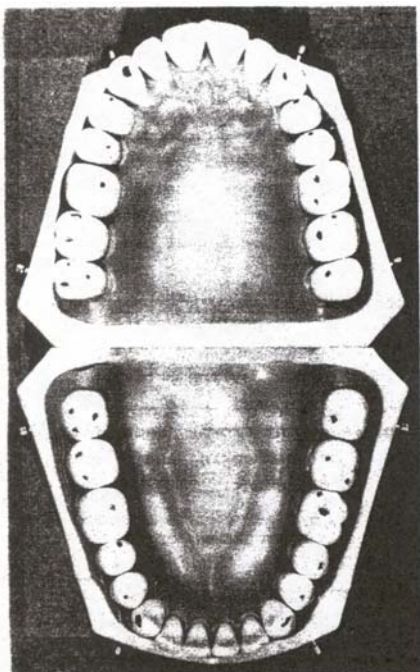
Blue marks on the slopes of cusps or on marginal ridges indicate destructive forces and are unacceptable. IF they occur, continue articulating until you achieve an acceptable occlusion. Since teeth in dentoforms are difficult to maneuver and to maintain in ideal occlusal relationships, it will only be necessary to have one of the four centric marks at the same intensity as produced on the unprepared tooth, in order to fulfill the occlusal requirement when the crown has been placed. (Acceptable occlusion in a dentoform is shown in Figure 4).

FIGURE 3 - TOOTH-TO-TWO TEETH CENTRIC CONTACT



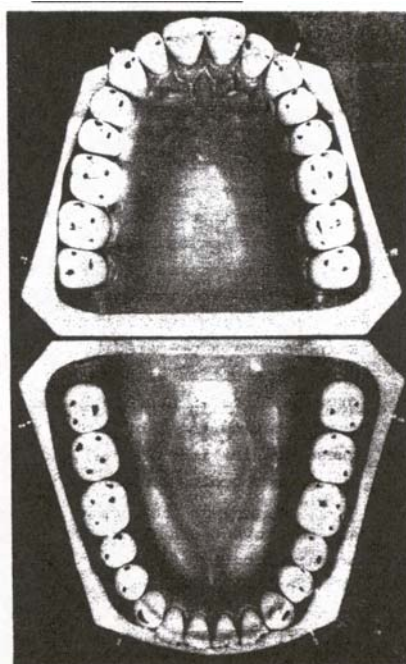
Tooth-to-two-teeth centric contact of posterior teeth.

FIGURE 4 - PATTERN OF OCCLUSAL MARKINGS



Model teeth showing a patter of occlusal markings acceptable in dentoforms. markings.

FIGURE 5 – IDEAL PATTERNS OF OCCLUSAL MARKINGS



Model teeth showing the ideal patterns of occlusal markings.

TEMPORARY CEMENT

Temporary cement is used to hold the restoration in place. It fills the space between the crown and the preparation, thus supporting the occlusal contours, filling and sealing the margin/finish line area.

During cementation it is imperative to remove all debris, to rinse and dry (not to desiccate causing sensitivity to exposed dentinal tubules) the preparation, and to isolate the area with cotton rolls to prevent contamination by saliva. Depending on the consistency of the cement mix, cement creates pressure as it dries, occasionally forcing the crown in an occlusal direction. This can be detected by a post-cementation occlusal check. Minor occlusal prematurities (high contacts) can generally be adjusted with the crown in the patient's mouth. Gross malocclusion (deviation from acceptable contact) will also tend to lift the crown from the preparation finish line; adjustment necessitates removal and re-cementation of the crown. Holding the teeth firmly together in centric occlusion during cementation should prevent most of these problems.

PLACING TEMPORARY CROWNS

Although the placement of each type of temporary crown is different, there are some conditions that must be met in order for a temporary restoration to be satisfactory:

(1) The margin of the crown must fit snugly against the finish line of the preparation and (2) must be sealed so that no oral fluids seep into the prepared area. (3) The contacts with adjacent teeth and (4) the occlusal pattern that exists before the tooth is prepared must be replicated not only when the finished crown is placed, but also while the temporary crown is in service (5) The facial and lingual contours must be similar to original and adjacent teeth and (6) surfaces should be smooth.

Many criteria for accomplishing the tasks that are described are stated in terms of a range of acceptable adjustment. A small degree of error in some areas will not distort the fit of the restoration or disturb the patient. The allowable errors for any temporary crown are:

1. The crown margin may be up to 0.5 mm short of (occlusal to) the preparation finish line. Marginal error away from the gingiva will not cause gingival irritation, whereas 0.5 mm toward the gingiva would be unacceptable. Up to 0.5 mm distance between the crown margin and the preparation finish line can be filled with cement without distorting fit or seal. This area is also protected by the gingiva since the finish line is normally apical to the gingival crest.
2. Assuming ideal gingiva, the facial and lingual surfaces of a crown may be slightly over-contoured without disturbing healthy tissue. Gross convexities, however, would create areas where food and bacteria could lodge.
3. Under-contouring in the gingival third on the interproximal surfaces is preferable to over-contouring, as it will not produce gingival pressure and irritation.

In an instructional setting, the student strives to produce a temporary crown that is "perfect"; however, in a clinical situation, temporary crowns frequently do not fit "perfectly" because the time to achieve perfection is too great, the crown is only temporary and the patient's oral health is not jeopardized.

ASEPTIC TECHNIQUE

Prevention of disease transmission by careful attention to aseptic technique before, during and after temporary restoration is required, as it is for all intra-oral procedures. Infection control guidelines for dental offices that have been published by the Center for Disease Control should be followed. Personal protection and barrier protection measures should be followed (e.g., gloves, mask, protective eye wear and lab coat). Cross-contamination should be avoided. Do not touch instruments, areas which have not been sterilized or disinfected. Practice proper hand washing techniques, properly clean, sanitize disinfect or sterilize all instruments and equipment.

The patient treatment area should be clean, orderly and as sanitary as possible before, during and after use. The laboratory area used for clinical practice should also be kept as clean and orderly as possible. You are encouraged to be conservative with your dental materials, to keep mixtures of alginate, acrylic resins, and cements in small areas on the mixing pad and in the mixing bowl, to produce the best mix; and to perform all cutting, trimming, contouring, and finishing outside the mouth, clear of the dentoform, as you would with a patient. An efficient technique will result from having developed habits such as these.

Module 2

Placing a preformed aluminum temporary crown

MODULE 2

PLACING A PERFORMED ALUMINUM TEMPORARY CROWN

Module 2 details the procedure for placing a temporary aluminum anatomical crown on the mandibular left second molar (#18). This crown on the mandibular left second molar posterior teeth that have been prepared for full crowns. The chief advantage of the temporary aluminum crown is its malleability, which allows for good occlusal adjustment. Such aluminum crowns are used only on molars and premolars, where aesthetics is not a primary consideration.

Temporary aluminum crowns are thin-walled (slightly less than 0.5 mm) tooth-shaped shells, commercially produced to conform ideal tooth anatomy. They are available in a range of sizes sufficient to cover most preparations. Although there is no sizing convention among manufacturers, preformed metal temporary crowns typically are produced for both molars and premolars and differ in size and occlusal anatomy. The aluminum crown is short and easily shaped so the idealized occlusal anatomy can be partially shaped into occlusion by the opposing teeth. Because these crowns are so soft, they must be handled gently.

Overview of Procedure

The first step in preparing a tooth for a temporary crown is to check occlusion, determining where the normal centric marks appear on the teeth. The dentiform should exhibit occlusal markings on every tooth except the incisors. The identical pattern of markings, with the same intensity as noted before preparation, should be replicated after placement of the temporary crowns.

After the tooth has been prepared, an impression is made and a cast is made and sent to the laboratory, where the crown is fabricated.

The mesio-distal space of the tooth to be restored is the primary dimension to be considered in selecting the crown. Because natural teeth vary in size and shape, it is unlikely that any preformed crown will ever fit a tooth without adjustment. When the best-fitting crown has been selected, it is then cut to the appropriate length, the edges crimped (bent upwardly) with hand instruments until proper fit is achieved. The rough edges of the crown are smoothed, and when proper occlusion is re-established, the crown is cemented over the preparation.

This temporary restoration procedure requires that you first study the contour of the unprepared tooth, certain features of which must be duplicated on the aluminum shell. Next, you should have an understanding of the slope of the chamfered enamel to the finish line of the prepared tooth, to help visualize the trimming and contouring required for the crown to fit snugly. To protect the prepared tooth, the ideal preparation is shaped to ensure good marginal seal when the crown margin is trimmed and crimped to hug the finish line of the preparation. Finally, attention the occlusal plane and centric contacts will help replicate pre-preparation occlusion, which is to preserve tooth alignment and to ensure patient comfort.

Figure 6 shows the mesial view of the proximal surface of tooth #18.
 Figure 7 shows the facial view of tooth #18 unprepared (a) and prepared with crown (b).

Figure 8 shows the lingual view of the unprepared tooth and the crown.

Figure 9 illustrates the occlusal view of the unprepared tooth; the broken line indicates the finish line.

FIGURE 6 MESIAL VIEW OF TOOTH #18


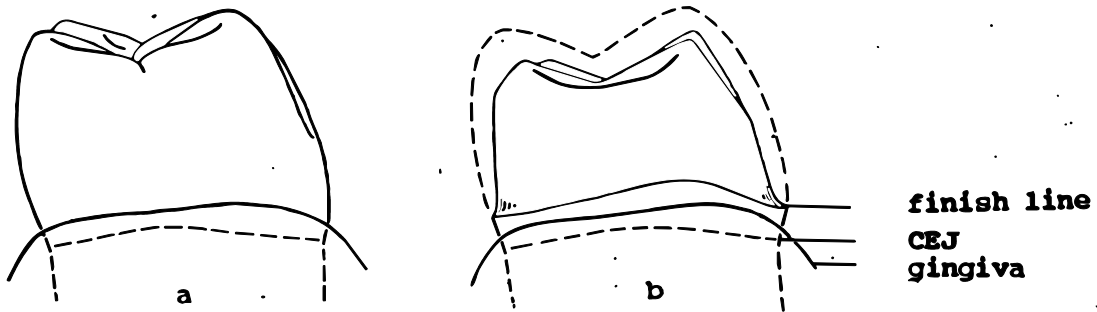
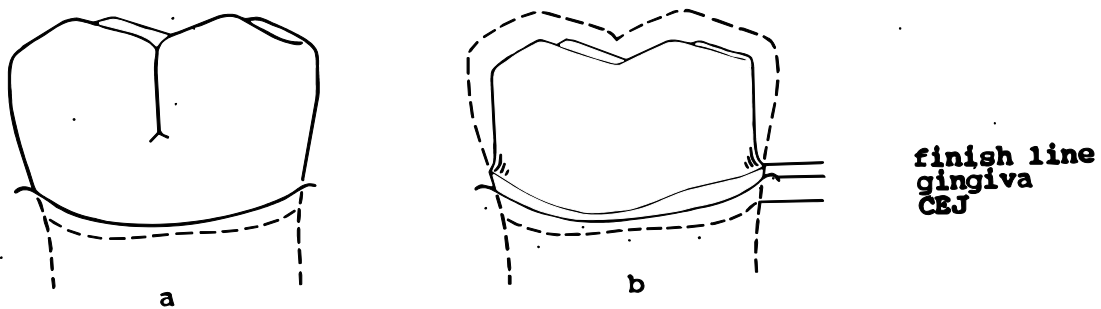


FIGURE 7 FACIAL VIEW OF TOOTH #18



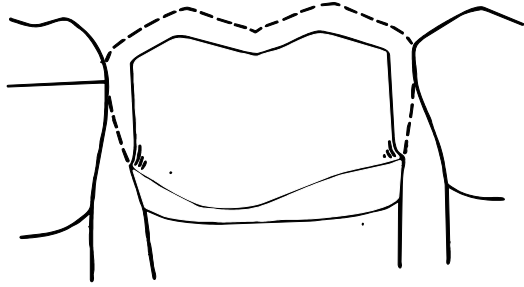
Mesial view of proximal surface of unprepared tooth #18 (a); prepared tooth with broken line indicating crown (b).

FIGURE 8 LINGUAL VIEW OF TOOTH #18

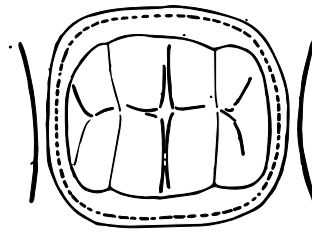


Facial view of unprepared tooth #18 (a); prepared tooth and crown (b).

FIGURE 9 OCCLUSAL VIEW OF TOOTH #18



Lingual view of prepared tooth with crown.



Occlusal view of prepared tooth #18.

ARMAMENTARIUM

1. PPE
2. Typodont with prepared tooth
3. articulating paper
4. millimeter rule
5. assortment of preformed anatomical aluminum alloy crowns for tooth
6. dental mirror
7. curved crown and bridge scissors
8. explorer
9. contouring pliers
10. dental floss
11. T-ball, flat-tail burnisher or beveling pliers
12. sandpaper disc (fine, medium garnet)
13. mandrels
14. pumice—impregnated rubber wheel
15. cotton rolls
16. lubricant (petroleum jelly or cocoa butter)
17. mixing pad and spatula
18. handpiece, contra-angle-latch type

PROCEDURES

Preliminary Procedures

1. **CHECK TO BE SURE YOU HAVE ALL THE SUPPLIES LISTED IN THE ARMAMENTARIUM.**
2. **CHECK THE OCCLUSION** of the unprepared tooth on dentoform. Place blue articulating paper between the left maxillary and mandibular arches, and gently tap the teeth together in centric occlusion. There must be at least one occlusal mark on each tooth in both arches. This occlusal pattern must be replicated with the temporary crown.
3. **PLACE THE PREPARED TOOTH IN THE DENTIFORM.** Retain the unprepared tooth with its occlusal markings for future reference.
4. **VISUALLY AND TACTUALLY LOCATE THE FINISH LINE** of the preparation with the explorer and the mirror.

Crown Placement Procedures

1. **MEASURE MESIO-DISTAL SPACE AT THE CONTACT AREA AND SELECT THE CROWN.**

Retract the cheek with the dental mirror, and use a millimeter ruler to measure the width of the mesio-distal space from the contact area of the left third molar #17, to the contact area of #19 molar in the middle third of the tooth. Select a crown whose width is equal to or greater than the measurement. It is better to select a crown that is slightly larger than the space, rather than too small, because the crown can be trimmed and shaped to fit. A crown that fits the mesio-distal space, is long enough occluso-gingivally and can be modified to fit snugly at the finish line.

Criterion

- a. Procedure completed
2. **TRY THE CROWN, AND CHECK ITS FIT**

Orient the crown, and , using finger pressure, gently push it over the preparation until it is seated. The crown can be adjusted to approximate the contours of the unprepared tooth and to re-establish occlusal and proximal contacts if the following relationships are observed:

 - a. The crown fits the mesio-distal space.
 - b. The facial and lingual contours of the crown should be in the same plane as those of the adjacent teeth. Use direct and indirect (mirror) vision to sight along the quadrant mesio-distally to make sure that the crown is not rotated or tilted on the preparation.

- c. The crown should encompass the finish line of the preparation. If the crown is so long that it cannot be seated but it nevertheless meets the mesio-distal and facio-lingual size and contour criteria, it can probably be shortened to fit. If the crown margin is short of the finish line, it is too short, and another crown must be selected. Try crown forms until one meets the criteria.
- d. The occlusal surface of the crown should be at or slightly above the occlusal plane of the adjacent teeth. Hold the mirror at the facial to view the occlusal plane additional guide to proper seating, by comparing their level to those of the adjacent molars.

Criteria

- a. The crown fits the mesio-distal space.
- b. The facial and lingual contours of the crown are in the same planes as those of the adjacent teeth.
- c. The crown margin meets or extends gingival to the preparation finish line.
- d. The occlusal surface and the marginal ridges of the crown are in a plane with, or within in 0.5 mm occlusal to the occlusal surface and the marginal ridges of the adjacent molars.

This is the first criteria stage of crown placement. It requires you to determine size and contour criteria visually. Be aware of minute shifts in the position of the crown and how they affect alignment with the adjacent teeth.

3. SCRIBE A TRIM LINE ON THE CROWN THAT FOLLOWS THE FINISH LINE CONTOUR.

The crown length usually needs adjustment. If the occlusal surface of the crown is above the occlusal plane of the adjacent teeth and the crown margin extends gingivally beyond the preparation finish line, the crown margin can be trimmed slightly to lower the occlusal surface. Study the contour of the preparation finish line with the dental mirror. With the crown fully seated on the preparation exactly. The level and contour of the preparation will be your guides for trimming the crown margin.

There are two methods of determining the trim line. Both are indirect and require you to visualize a reference point while scribing the trim line on the facial and lingual surfaces of the crown with an explorer. In one method hold the crown on the preparation, covering the preparation finish line, scribe a corresponding trim line along the marginal portion of the crown with an explorer. You may want to use the dental mirror to stabilize the crown while scribing. By the other method, hold the crown just above the preparation finish line so that its contour can be copied on the facial and lingual surfaces of the crown as you visualize the amount of trimming that is necessary. The contours of occluso-gingival height. Since this may require several attempts, it is advisable to trim only a small amount at a time thereby avoiding over-trimming.

Criterion

- a. Trim line scribed along the marginal area of the crown.

4. ADJUST THE LENGTH OF THE CROWN.

Remove the crown from the preparation, and use the curved crown and bridge scissors to trim the crown margin to the scribed line. Begin trimming at a line angle (the junction of two horizontal adjacent tooth surfaces, such as mesial and facial), making sure that the curve of the blades follows the curve to be trimmed. Trim the interproximal areas of the crown with the same contours as the interproximal area of the preparation finish line. Use care not to cut the margin too short. Any sharp curve left after cutting must be blended into a smooth line.

The crown is held high as a trim line replicating the reparation finish line is scribed on it.

Then the crown is trimmed, replace it on the preparation and inspect the margin of the crown to see how it conforms to the finish line. Check this by holding the explorer firmly against the finish line and then following along its contour. The crown margin should coincide with the finish line. Check that the marginal ridges of the crown are at or within 0.5 mm occlusal to the marginal ridges of the adjacent molars.

Criteria

- a. Crown is trimmed so that its margin meets and conforms to the contours of the preparation finish line.
- b. Crown margin is free of sharp edges.
- c. Occlusal plane of crown is at or 0.5 mm occlusal to that of the adjacent teeth.

5. REDUCE THE CIRCUMFERENCE OF THE CROWN MARGIN.

When a crown fits the mesio-distal space, it will probably not fit the gingival margin of the preparation. To reduce the circumference of the crown margin, use a pair contouring pliers to crimp (bend inward) the edges of crown. While the crimping reduces the marginal circumference, the action of the pliers tends to distend the crown walls immediately occlusal to the margin. Besides reducing the circumference of the crown with crimping, the length of the crown is also reduced.

Use the contouring pliers to crimp inwardly and evenly around the gingival third of the crown until the crown fits snugly against the margin of the preparation. Work in small increments in order to maintain the general contour of the crown walls.

Check the marginal adaptation of the crown by placing it over the preparation and with a finger on the occlusal surface move the crown in a facio-lingual direction, noting where additional crimping is needed. Use the explorer tip in a gingivo-occlusal direction to determine where there is space between the crown and the preparation. You will notice only a slight catching as the explorer tip moves from enamel to aluminum if the margin is well-fitted. If the explorer catches in a space under the crown, more crimping is required. Interproximal areas of the

crown margin are particularly difficult to check and need careful attention. Continue to crimp and check the crown on the preparation until the crown fits firmly against the finish line of the preparation. When the marginal circumference of the crown is sufficiently reduced, a slight clicking sound is produced when it contacts the preparation margin. Caution: There is also a clicking sound when the crown is too long and snaps over the margin.

Criteria

- a. Crown margin conforms to the contour of the preparation finish line.
- b. Crown walls show no convexities or distensions.

6. SMOOTH THE EDGES OF THE CROWN.

Use the straight handpiece and a sandpaper disc with short, light strokes to smooth any rough edges on the crown margin. Clean all debris from the crown.

Criterion

- a. Crown margin is a smooth curve free of sharp edges and debris.

7. DEVELOP THE CROWN'S OCCLUSAL ANATOMY.

Seat the crown on the preparation, and close the mandible into centric occlusion with slight pressure. The opposing teeth should impress and shape the occlusal surface of the crown. Take care to exert only slight force, as excessive pressure will be filled with cement so the final occlusal features can be safely developed with slightly more pressure.

Criterion

- a. Preliminary occlusal anatomy of the crown is impressed on the crown.

8. CHECK OCCLUSION.

Clean and dry preparation, and use the air jet to dry all other teeth.

Place articulating paper between the arches, and tap the teeth into centric occlusion. Examine the teeth in the quadrant for margins; at least one point of contact should be present on each tooth. Compare with pre-preparation markings. If there are more and/or darker marks on the crown than were perceived at the pre-preparation check, or if only the maxillary teeth and the temporary crown show marks from the articulating paper, the crown is in supraocclusion (too high). To reduce the heights of the crown, trim, re-crimp, smooth the margin, clean the crown, and check the occlusion again. If no marks register on the crown, it is in infra-occlusion (too low), and you must fit a new crown.

Criterion

- a. Pre-preparation occlusion is replicated, and all the teeth, including the crown, produce at least one occlusal contact mark of the same intensity as they did in the pre-preparation check.

9. CHECK CONTACT

Check for proximal contacts by passing a length of dental floss through both the mesial and the distal contact areas. The floss should meet some resistance, but should snap through the contact areas. Remove floss through the embrasure, so as not to dislodge the crown.

If there is no contact, remove the crown. Place the crown on a paper pad for cushioning, and with the ball end of the T-ball burnisher, impress an ovoid shape on the inner facial surface. The burnishing will stretch the aluminum outward, to produce a convexity and establish contact. Replace the crown, and recheck.

If a contact is too tight, use contouring pliers to bend and flatten the contact area. If the marginal area is deformed during this process, some re-crimping may be necessary.

Criterion

- a. The crown has a smooth margin and is free of debris.

10. SMOOTH CROWN

When you are satisfied that the crown meets all criteria related to margin, contacts, and occlusion, use a rubber wheel impregnated with pumice in the handpiece to smooth the margin. Polish off any written identification on the crown, taking care not to deform any contours. Use the air jet to clean the crown of debris.

Criterion

- a. The crown has a smooth margin and is free of debris.

11. CEMENT TEMPORARY CROWN ON PREPARATION

Lubricate the exterior of the crown with petroleum jelly so excess cement will be easier to remove. Rinse and air dry the preparation but do not desiccate the tooth. When working with a patient, it is necessary to place a cotton roll between the cheek and the preparation and another between the tongue and the preparation, to keep the tooth dry (cement will not adhere if the preparation is too moist).

Prepare a mix of temporary cement according to the manufacturer's directions. When the cement is of uniform consistency and flows slowly from the end of the spatula coat all internal surfaces of the crown. Add additional cement so that the crown is from one-third to one-half full.

Place the crown in its predetermined position on the preparation; use the marginal ridges of the adjacent teeth as a guide for proper seating then use an explorer to check that the crown is seated. Gently bring the mandible into occlusion and maintain centric occlusal contact until the cement sets. This contact will further shape the occlusal surface of the crown. Avoid excess pressure, as it can produce infra-occlusion.

The cement is set when the tip of the explorer does not penetrate its surface. After the cement has set, use an explorer to carefully remove all excess cement from interproximal areas and the gingival margin. Since small chips of cement can easily get embedded in the gingival sulcus, remove the excess cement in the largest pieces possible. Floss the contact areas to remove any cement chips in the proximal areas, adding a knot to the floss will help. Remember to remove the floss laterally not up through the contact.

Remove the cotton rolls, and thoroughly rinse and dry the restoration area.

Criteria

- a. Crown contacts with the adjacent: mesially, distally.
- b. Facial and lingual surfaces are in the same plane as the adjacent teeth.
- c. Crown margins:
 - Ranges from the preparation finish line to 0.5 mm occlusally of the finish line.
 - Fits snugly against the finish line.
- d. Excess cement removed from interproximal and gingival areas.

12. MAKE FINAL CHECK FOR OCCLUSION

Place articulating paper between the teeth, and perform a post-cementation check of the occlusion of the entire arch. Should the crown be in infra-occlusion, it will be necessary either to remove it and re-contour its occlusal surface or to adapt a new crown form.

Criteria

- a. There is at least one centric mark on the crown that is of the same intensity as those on the adjacent teeth.
- b. There is at least one centric mark on each tooth.

SUMMARY OF PROCEDURES AND CRITERIA

| <u>Procedures</u> | <u>Criteria</u> |
|--|--|
| 1. Measure mesio-distal space at the contact area, and select the crown. | a. Procedure complete. |
| 2. Try the crown, and check its fit. | <ul style="list-style-type: none"> a. The crown fits the mesio-distal space. b. Facial and lingual contours of the crown are in the adjacent teeth. c. Crown extends gingivally from preparation finish line. d. The occlusal surface and the marginal ridges of the crown are in a plane with, or within 0.5 mm occlusal to, the occlusal surface and the marginal ridges of the adjacent molars. |
| 3. Scribe a trim line on the crown that follows the finish line contour. | a. Trim line scribed along the marginal area of the crown |
| 4. Adjust the length of crown. | <ul style="list-style-type: none"> a. Crown is trimmed so that its margin meets and conforms to the contours of the preparation finish line. b. Crown margin is free of sharp edges. c. Occlusal plane of crown is at or 0.5 mm occlusal to that of the adjacent teeth. |
| 5. Reduce the circumference of the crown margin. | <ul style="list-style-type: none"> a. Crown margin is crimped to hug the preparation finish line. b. Crown walls show no convexities or distensions. |
| 6. Smooth the edge of the crown. | a. Crown margin is a smooth curve free of sharp edges and debris. |
| 7. Develop the crown's occlusal anatomy | <ul style="list-style-type: none"> a. Preliminary occlusal anatomy of the crown is impressed. |

8. Check occlusion.

 - a. Pre-prepared occlusion is replicated, and all the teeth, including the crown, produce at least one occlusal contact mark of the same intensity as they did in the pre-preparation check.
9. Check contacts.

 - a. Interproximal contacts are established between the crown and the adjacent teeth.
10. Smooth crown.

 - a. Crown has a smooth margin and is free of debris.
11. Cement temporary crown on preparation.

 - a. Crown contacts with the Adjacent teeth: distally, mesially.
 - b. Facial and lingual surfaces are in the same plane as the adjacent teeth.
 - c. Crown margin:
 - Ranges from the preparation finish line to 0.5 mm occlusally of the finish line.
 - Fits snugly against the finish line.
 - d. Excess cement removed from Interproximal and gingival areas.
12. Make final check for occlusion.

 - a. There is at least one centric mark on the crown that is the same intensity as those on the adjacent teeth.
 - b. There is at least one centric mark on each tooth.

Module 3

Placing a preformed plastic temporary crown

MODULE 3

PLACING A PREFORMED POLYCARBONATE TEMPORARY CROWN

The crown used in this module is polycarbonate (a form of synthetic resin). This material is widely used for temporary crowns for several reasons: it is strong yet flexible enough to contour easily; it bonds chemically to a self-curing acrylic resin material used to fill the shell. Although plastic crowns do not bend and draw as metal crowns do, they have almost perfect bonding properties. Any area of a plastic crown, including the incisal edge, can be extended by adding layers of acrylic and smooth them.

Plastic crowns are commercially produced to conform to standard surface contours of teeth and are available in a range of sizes sufficient to cover most preparations. Although the manufacturers have no sizing convention, the sizes of most polycarbonate crowns vary by increments of approximately 0.5 mm mesio-distally. Incisal crowns, when fitted to preparations mesio-distally, are generally too wide facio-lingually.

In this module the maxillary right permanent central incisor (#8) is to be temporarily restored with a preformed polycarbonate temporary crown. The tooth has been prepared for a permanent porcelain-fused-to-metal crown. Figure 13 presents facial and mesial views of the unprepared tooth and the prepared tooth with a crown.

incisor (#8) is to be temporarily restored with a preformed polycarbonate temporary crown. The tooth has been prepared for a permanent porcelain-fused-to-metal crown. Figure 13 presents facial and mesial views of the unprepared tooth and the prepared tooth with a crown.

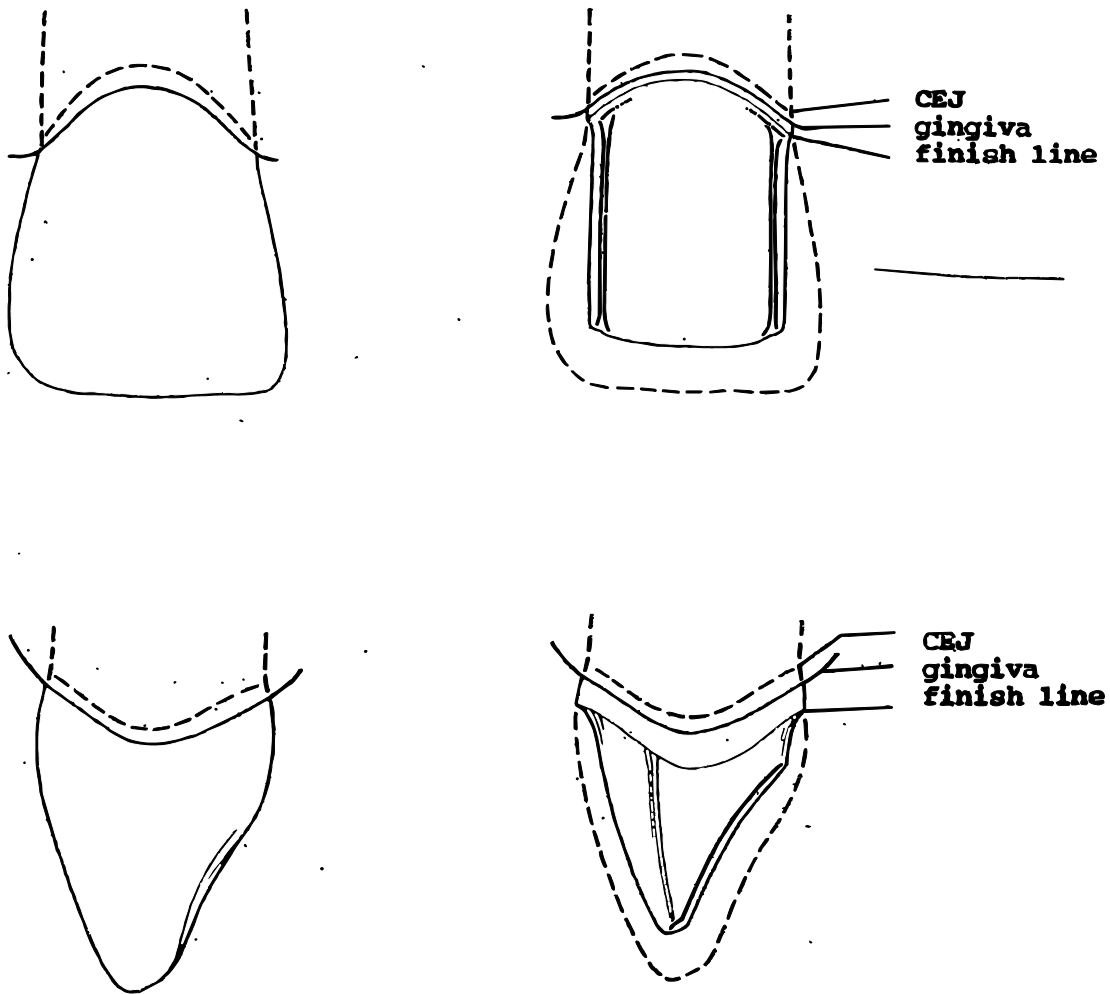
Overview of Procedure

The procedure for temporarily restoring this tooth with a preformed plastic crown begins and ends with occlusion checks. After occlusion is checked, a preformed plastic crown that will cover the prepared tooth and contact the adjacent teeth is selected. The size of the crown is determined by measuring the space between the mesial and distal contacts of the tooth with a Boley gauge.

As the plastic shell is placed over the tooth, it will be immediately obvious that the internal form of the crown does not approximately that of the preparation. The crown must be in place, marked and trimmed until the crown margin conforms to the contour of the finish line of the preparation. An acrylic resin is then mixed and placed in the crown, which is subsequently seated on the preparation. The viscous resin fills the spaces between the prepared tooth and the crown and as the acrylic resin hardens, the contours of the pre-prepared tooth are replicated. With the crown in place, occlusion is checked; then extra resin removed the margin of the crown trimmed, the incisal length adjusted, and contacts established. Finally, the crown is cemented in place and a last occlusion check is made.

Success in placing this crown depends on careful trimming and contouring of the polycarbonate crown shell and the acrylic resin.

FIGURE 13
FACIAL/MESIAL VIEWS OF TOOTH #8



**Facial (at top) and mesial view of tooth #8,
unprepared and prepared.**

ARMAMENTARIUM

1. PPE
2. articulating paper and holder
3. typodont with prepared tooth
4. assortment of preformed polycarbonate temporary crowns for tooth
5. explorer
6. dental mirror
7. round bur (#6 or #8)
8. flame-shaped acrylic bur
9. green stone
10. sharpened soft lead pencil (#1)
11. curved crown and bridge scissors
12. cotton rolls
13. lubricant (petroleum jelly or cocoa butter)
14. dappen dishes
15. acrylic resin kit
16. spatula (#7)
17. gauze pads (2" x 2")
18. excavator
19. boley gauge or micrometer caliper
20. unwaxed dental floss
21. mandrels (Moore's)
22. coarse garnet disc (3/4")
23. fine cuttle disc (3/4")
24. fine pumice (optional)
25. buffing wheel (optional)
26. temporary cement kit
27. mixing pad double-ended plastic instrument
28. low speed straight and contra angle handpiece

PROCEDURES

Preliminary Procedure

Before the temporary plastic crown placement procedure is begun on a patient, the anterior maxillary quadrant should be thoroughly cleaned to remove plaque and debris, the occlusion the quadrant should be checked, and maxillary right central incisor #8 should be prepared for ultimate placement of the porcelain-fused-to-metal permanent full crown.

1. Check the Armamentarium to be sure you have all the necessary supplies and equipment.
2. Remove the unprepared tooth from the dentoform after checking occlusion, and set it aside for later reference. Note whether the tooth was in occlusion.
3. Place the prepared tooth in the dentoform.

Crown Placement Procedure

1. MEASURE THE MESIO-DISTAL SPACE BETWEEN THE CONTACT AREAS, AND SELECT THE CROWN.

With a micrometer caliper (or boley gauge), measure the space between the mesial and the distal contact areas of the tooth #8 at the level of the incisal third of the adjacent teeth. From the selection of sample crowns, choose a crown that is the same size or wider than the space. (A wider crown ensures an adequate lining of acrylic all around the preparation).

To facilitate placing on and removing the crown from the preparation, maintain the tab on the incisal edge.

- a. Procedure completed.
2. TRY THE CROWN FOR FIT, AND ADJUST THE BINDING.

Gently press the crown over the prepared tooth; keep the facial surface in the same plane as those of the adjacent teeth. There should be enough clearance between the preparation and the crown to allow the crown margins to reach the finish line of the preparation. Almost any crown will need adjustment to fit; following are some of the common problems and solutions.

- a. If the crown fits mesio-distally, but is too tight internally preventing the crown from meeting the preparation finish line, use a round bur in a straight handpiece at low speed to adjust the interior of the crown. You may need to place and remove the crown several times to determine the exact point of binding; take care to place the crown in exactly the same position each time you place it on the preparation.

- b. If the crown should bind at the preparation's finish line, increase the marginal diameter with an acrylic bur. Determine with an explorer the exact place of binding, usually in an interproximal area.
- c. If the proximal surfaces of the crown bind on the adjacent teeth, but a smaller preformed crown is too narrow to make contact, remove a small amount of plastic from the contact areas with an acrylic bur in the straight handpiece. Should you accidentally perforate the plastic crown, you can correct it later by adding acrylic.
- d. When the crown has been adjusted to fit mesio-distally, there usually remains several other adjustments to be made. Typically the crown extends gingivally over the finish line, is longer at the incisal edge than the adjacent tooth and is too wide facio-lingually at the finish line. Don't expect a perfect fit too soon; these adjustments will be made later in the procedure.

Criteria

- a. Crown fits the mesio-distal space of the tooth to be restored.
- b. Crown fits over preparation without binding.
- c. Crown contacts adjacent teeth.

3. ADJUST GINGIVAL LENGTH OF MARGIN AND MARGINAL CONTOUR OF CROWN.

In this step, the margin of the crown will be grossly trimmed; final fitting will take place after the crown has been lined. The crown margin should be just gingival to the finish line so that the acrylic lining will be able to flow freely, extruding all around the margin and thus reproducing the finish line of the preparation.

Study the contour and location of the finish line, place the crown over the preparation and with a sharpened soft lead pencil mark the finish line. Remove the crown and with the curved crown and bridge scissors, begin trimming the gingival margin of the crown at the facial. Cutting carefully toward the proximal, trim only a small amount of plastic at a time, results if large pieces are cut. Place the crown on the tooth occasionally to check how closely the margin conforms to the finish line.

This same procedure can be achieved with the acrylic bur in the straight handpiece, holding the handpiece in a palm grasp. Assume a thumb-to-thumb finger rest; trim, thin, and smooth the crown margin until it is smooth and of uniform thickness. When the crown is in place over the preparation, the preparation finish line should be just visible where the crown margin meets the prepared tooth. Use the mouth mirror to view the lingual marginal area. Replace the crown on the tooth occasionally to check how closely the margin conforms to the finish line.

It is important to seat the crown in the same position each time you try it on the preparation. The adjacent central incisal edge and facial surface can serve as guides for this. When you line the crown up on any one plane, you should sight from two vantage points 90 apart; for example, view the facial plane from the incisal edge and from the distal side.

Criteria

- a. Crown margin fits over preparation.
- b. Crown margin approximates the finish line contour and extends slightly gingival to the finish line.
- c. Crown margin is smooth and of uniform thickness.
- d. Major areas that will need re-contouring are noted.

4. CLEAN AND DRY THE PREPARATION AND CROWN, ISOLATE THE AREA, AND LUBRICATE THE PREPARATION AND THE ADJACENT TEETH.

Clean and dry the preparation with water and a flow of air. Clean all debris from the crown, and dry the crown with air pressure. Since moisture will interfere with acrylic polymerization, place a cotton roll between the lip and the gingiva. To prevent the acrylic from adhering to the preparation, the adjacent teeth and the gingiva, coat a cotton roll with some petroleum jelly and lubricate the areas. Remember that the lubricant will contaminate the acrylic resin during polymerization so that it will not bond properly with any additional acrylic resin you might wish to add later.

Criterion

- a. Procedure completed.

5. FILL THE CROWN WITH ACRYLIC RESIN, AND SEAT IT ON THE PREPARATION.

Seat the crown on the preparation in the exact position for which the margin has been trimmed, and not its alignment. Once it is fully seated, hold the facial surface of the crown flush with that of the adjacent central incisor for correct positioning. This position will have to be duplicated when the crown is filled with acrylic resin.

For the placement of the crown, it is assumed that a larger quantity of acrylic resin will be needed. Follow the manufacturer's directions exactly. Place a few drops of monomer in a dappen dish and add polymer; mix the monomer and polymer with a spatula or tap on the counter to incorporate thoroughly and to eliminate air entrapment. When the resin mix has a creamy consistency, use a spatula to apply a thick coat to the interior of the crown. Begin at the incisal depth of the crown, filling carefully so bubbles do not form. Coat the walls thoroughly, filling the crown until there is only a shallow concave surface of acrylic resin at the marginal end of the crown. Avoid overfilling the crown.

When the acrylic resin loses its highlights and surface shine (after about one minute), seat the crown on the prepared tooth, taking care not to rotate it from its correct position. Hold the facial and incisal surface stable with your forefinger on the crown and the adjacent central incisor for 2 or 3 minutes. Be especially careful to guard against mesial and distal rotation.

The acrylic resin will fill the space between the crown and the preparation and the excess will flow gingivally covering the finish line.

If only a small amount is needed to fill a void or to extend a contact area, the bead-brush or the brush-flow technique is recommended. For this, you line up three dappen dishes, shallow end up. Place a drop or two of monomer in each of the first and second dishes (one of these is for rinsing the brush) and a little polymer in the third dish. Dip the brush in the monomer; then touch it to the powder, to form a bead on the tip of the brush. Brush the bead onto the crown where it is needed, and smooth it in place with the brush. Rinse the brush in the rinsing dish of monomer, and wipe it on a piece of gauze before dipping it into the clean monomer and then into the polymer again, to form another bead; and apply it as before.

Criteria

- a. Polymer and monomer are mixed thoroughly to a cream consistency.
 - b. Crown interior is almost completely filled with acrylic resin, which forms a shallow concave surface at the marginal end of the crown.
 - c. Crown fully seated on the preparation, with its facial surface flush with that of the adjacent central incisor.
 - d. Resin has extruded over the finish line.
6. **REMOVE CROWN AND TRIM AWAY EXCESS ACRYLIC RESIN.**

Excess acrylic resin must be removed from the crown before it is completely hard to prevent the crown from binding interproximally. If the acrylic resin hardens before trimming, the crown or the tooth may break when you attempt to remove the crown. Use the explorer to check the consistency of the excess resin at the margins. When the resin has become doughy (when it does not run and has little stretch to it), remove the crown from the tooth. Using the crown and bridge scissors, trim away the excess acrylic resin.

Criterion

- a. Margin is free of gross excess resin.
7. **RESEAT CROWN WHILE POLYMERIZATION IS COMPLETED.**

Immediately reseat the crown. Stabilize the crown with your finger. Test the marginal acrylic resin with the explorer. At this point, you may want to take the crown on and off the preparation a few times. When the explorer cannot indent the acrylic resin, polymerization is complete.

Remove the crown. Should this be difficult, use a piece of gauze to get a purchase on the crown. If the crown still does not unseat, gently pry around the margin with an excavator. If needed, use Backus towel clamps to pull the crown off.

Use a magnifying glass to examine the internal surfaces of the crown and the marginal area. The preparation and the finish line should be replicated; acrylic resin should be free of large voids. If 95% of the finish line is not successfully replicated, fit a new crown; small voids can be filled.

Replace the crown over the preparation. It should fit snugly, and it should resist if you try to move it with your finger.

Criteria

- a. Acrylic resin liner has polymerized; it is hard.
- b. The preparation and at least 95% of the finish line is impressed in the acrylic resin.
- c. Acrylic resin liner is free of large voids.
- d. Crown fits preparation snugly without binding.

8. TRIM CROWN MARGIN.

Remove the crown. Locate the impressed finish line of the preparation on the interior of the crown; mark it with a sharpened, soft lead pencil. The pencil line indicates the impressed finished line of the preparation. Use an acrylic bur to trim the resin that extends gingival of the finish line. Short intermittent strokes of the bur will reduce softening and tearing of the resin. As you trim the margin, clean away the debris and place it occasionally on the preparation until the margin conforms to the finish line.

Criteria

- a. Crown margin meets preparation finish line exactly.
- b. Crown is clean of debris.

9. ADJUST OCCLUSION, INCISAL LENGTH, FACIAL AND LINGUAL CONTOURS AND FACIO-LINGUAL WIDTH OF CROWN.

Gross occlusal adjustment is necessary at this time. For this step, first dry the prepared area, the crown, the adjacent maxillary teeth, and the opposing mandibular teeth. (Articulating paper will not mark a wet surface.) Seat the crown, place blue articulating paper between the maxillary and the mandibular incisors, and gently tap the teeth together. If the mark on the crown is heavier than the mark on the unprepared tooth (as it is likely to be), the lingual surface of the crown is too thick. Thin that area at the blue mark using the acrylic bur in the straight handpiece at low speed. After using the bur, use gauze to wipe all traces of blue from the teeth. Check occlusion again, and repeat the procedure until the crown occlusion replicates the occlusion of the unprepared tooth.

To check the incisal length of the crown, be sure the crown is fully seated, and compare the location of its incisal length of the crown, be sure the crown is fully seated, and compare the location of its incisal edge with that of the adjacent central incisor. Use a sharpened, soft lead pencil to draw a line from mesial to distal across the facial surface of the crown, indicating where to trim. Remove the crown from the preparation, and break off the tab. Use the acrylic bur at low speed to trim the areas that require reduction. In some areas it may be necessary to trim away the plastic shell entirely and contour the underlying acrylic resin. Reseat the crown frequently to reassess the contours.

Use the mirror to compare the facial contour of the crown with that of the other central incisor. Hold the mirror to the distal of the lateral as you sight across the central incisors. Use a pencil to shade any area that needs reduction or addition.

In the majority of clinical situations, the finish line is sub gingival and the contour is critical because over-contouring in the area can cause gingival irritation and patient discomfort. Take time to examine the marginal area on the lingual surface carefully with the mirror and explorer. Check for any overhang that catches the explorer, and use various sighting techniques to compare the overall contour of the crown with that of the adjacent central incisor. Again, use a pencil to shade any areas that need adjustment.

Compare the facio-lingual width of the incisal edge of the crown with that of the other central after you have adjusted the incisal length. Shortening a crown increases the width of the incisal length. Shortening a crown increases the width of the incisal edge enough that facial and lingual contouring may be necessary to reduce that dimension on the crown.

Criteria

- a. Crown occlusion replicates the occlusion of the unprepared tooth.
- b. Tab is removed.
- c. Needed contouring is adjusted.
- d. Crown is the same length gingivo-incisally as tooth #9.

10. REFINE INCISAL, FACIAL AND LINGUAL CONTOURS, FACIO-LINGUAL WIDTH, AND INTERPROXIMAL AREAS.

If an area of the crown is under-contoured, acrylic resin may be added to the area by the bead-brush technique.

Last, inspect the crown for overall contour, and compare it to the adjacent central incisor. Check the interproximal contours in the gingival half, and remember that the patient's comfort and aesthetics depend upon your ability to reproduce the original, unprepared tooth.

Criteria

- a. Crown margin exactly meets the preparation finish line.
- b. Crown contour resembles that of tooth #9 facially, lingually, incisally, and interproximally in the gingival half.

11. CHECK AND ADJUST THE CONTACTS OF THE CROWN WITH THE ADJACENT TEETH.

Check the mesial and distal contacts of the crown with the adjacent teeth by using dental floss. If the floss encounters some resistance incisally but snaps

through, the contact is well established. When no contact exists, use the bead-brush technique to add acrylic resin to the incisal third of the crown on the proximal surface. Allow the resin to become doughy, and then seat the crown till the acrylic hardens, to establish the contact. Next, remove the crown, and smooth any pits or bumps with the acrylic bur. Should the contacts be so tight that the floss cannot pass through, use the acrylic bur to trim the incisal third. Replace the crown, and check that both contacts have been adequately established.

Criterion

- a. Mesial and distal contacts re-established.

12. REFINE THE CONTOUR, AND POLISH CROWN SURFACES.

While holding the crown in your hand, use the coarse garnet disc or acrylic bur in the handpiece with the thumb-to-thumb rest, to finish and refine the contour; exclude centric stops, crown margin, and interproximal contacts. Light pressure and intermittent strokes will minimize the generation of heat. Coat a fine cuttle disc with petroleum jelly, place it in the handpiece, and polish the crown until it is free of pits and rough areas or you may refine the crown surfaces on the late with a buffing wheel and a thin slurry of fine pumice.

Criterion

- a. All surfaces, except centric stops, margin, and interproximal contacts, are smooth and polished.

13. FINAL CHECK OF MARGINAL FIT, INTERPROXIMAL CONTACTS, AND OCCLUSION.

Rinse and dry the crown with the water and air spray, to clean away all debris. Reseat the crown, and check with the explorer that its margin meets the preparation finish line. The explorer should catch only slightly when moved in a gingivo-incisal direction along the junction of the margin and the finish line.

Use dental floss to check again for the presence of interproximal contacts. Then recheck the occlusion. The occlusion marks (if any) should replicate those noted before the procedure was begun. Remove the crown.

Criteria

- a. Crown margin exactly meets and fits the preparation finish line.
- b. Mesial and distal contacts re-established.
- c. Crown occlusion replicates the occlusion of the unprepared tooth.

14. CLEAN, DRY AND ISOLATE PREPARED TOOTH, AND LUBRICATE CROWN.

Isolate the anterior maxillary area with a cotton roll between the lip and the gingival. With a cotton roll lubricate the exterior surfaces of the crown with a light coating of petroleum jelly or cocoa butter, to prevent excess cement from adhering to the crown. Caution: no lubricant should contact the surfaces to be cemented.

Criteria

- a. Preparation is isolated with cotton rolls.
- b. Crown exterior is lubricated.

15. CEMENT THE CROWN ON THE PREPARATION.

Prepare a mix of temporary cement according to the manufacturer's directions. When the mixture is of uniform consistency, use a plastic instrument to coat the internal surfaces of the crown evenly with only a thin layer of cement. Dry the preparation with light air or a dry gauze. Place the crown on the preparation, and check the margin with the explorer to see whether it is properly seated. Insert a cotton roll between the maxillary and the mandibular incisors, and bring the teeth together, holding them with moderate pressure for about 3 minutes until the cement sets. (You can remove the extruded cement with the explorer after it dries to the point where the tip of the explorer does not penetrate its surface).

Criteria

- a. Temporary cement is mixed to uniform consistency.
- b. Interior of crown is coated with a thin layer of cement.
- c. Dry the preparation with light air pressure or with a dry gauze.
- d. Crown is fully seated on the preparation and hold in place by a cotton roll between maxillary and mandibular incisors until the cement is set.

16. CLEAN AND DRY THE CROWN AND ADJACENT TEETH.

Remove excess cement from the interproximal areas, the margins, and the sulcus with the explorer and an excavator; the cement can cause considerable irritation. Use dental floss to free the contact areas of cement. A knot added to restored tooth with gauze, remove the cotton roll, and wash and dry the entire area with the air/water spray.

Criterion

- a. Restored tooth and surrounding area are free of excess cement and are clean and dry.

19. FINAL CHECK OF OCCLUSION AND MARGIN.

Check the occlusion with blue articulating paper. Check the marginal seal with the explorer. Should incisal prematurities appear, trim and polish with the fine discs, and then check again.

Criteria

- a. Occlusion of the restored tooth replicated that of the unprepared tooth.
- b. Crown margin is sealed.

SUMMARY OF PROCEDURES AND CRITERIA

| Procedure | Criteria |
|---|--|
| 1. Measure the mesio-distal Space between the contact Areas, and select the crown. | a. Procedure completed. |
| 2. Try the crown for fit, and | a. Crown fits the mesio-distal space of the tooth to be restored. b. Crown fits over preparation without binding. c. Crown contacts adjacent teeth. |
| 3. Adjust gingival length and marginal contour of crown. | a. Crown margin fits over preparation. b. Crown margin approximates the finish line contour and extends slightly gingival to the finish line. c. Crown margin is smooth and of uniform thickness. d. Major areas that will need re-contouring are noted. |
| 4. Clean and dry preparation and crown, isolate the area, lubricate the preparation and adjacent teeth. | a. Procedure completed. |
| 5. Fill the crown with acrylic resin and seat it on the preparation. | a. Polymer and monomer is incorporated thoroughly to a creamy consistency eliminating air entrapment. b. Crown interior is almost completely filled with acrylic resin, which forms a shallow, concave surface at the marginal end of the crown. c. Crown is fully seated on the preparation with its facial surface flush with that of adjacent central incisor. d. Resin has extruded over the finish line. |

- | | | | |
|-----|--|----|---|
| 6. | Remove crown, and trim away excess acrylic resin. | a. | Margin is free of gross resin. |
| 7. | Reseat crown, and complete Polymerization. | a. | Acrylic resin liner is set. |
| | | b. | Interior of the crown replicates the preparation and at least 95% of the finish line is reverse. |
| | | c. | Acrylic resin liner is free of large voids. |
| | | d. | Crown fits preparation snugly without binding. |
| 8. | Trim crown margin. | a. | Crown margin meets preparation finish line exactly. |
| | | b. | Crown is clean of debris. |
| 9. | Adjust occlusion, incisal length, facial and lingual contours, facio-lingual Width of crown. | a. | Crown occlusion replicates the occlusion of the unprepared tooth. |
| | | b. | Tab is removed. |
| | | c. | Needed contouring is adjusted. |
| | | d. | Crown is the same length gingivo-incisally as tooth #9. |
| 10. | Adjust incisal length, facial and lingual contours, facio-lingual Width, and interproximal areas. | a. | Crown margin exactly meets the preparation finish line. |
| | | b. | Crown contour resembles that of tooth #9 facially, lingually, incisally, interproximally in the gingival half. |
| 11. | Check and adjust the contacts of the crown with the adjacent teeth. | a. | Mesial and distal contacts re-established. |
| 12. | Refine the contour, and polish crown surfaces. | a. | All crown surfaces, except Centric stops, margin and interproximal contacts, are smooth and polished. |
| 13. | Final check of marginal fit, interproximal contacts, and occlusion. | a. | Crown margin exactly meets and fits the preparation finish line. |
| | | b. | Mesial and distal contacts re-established. |
| | | c. | Crown occlusion replicates the occlusion of the unprepared tooth. |

- 14. Isolate the prepared tooth, and lubricate crown**

 - a. Preparation is isolated with cotton rolls.**
 - b. Crown exterior is lubricated.**

- 15. Cement the crown on the preparation.**

 - a. Temporary crown is mixed to uniform consistency.**
 - b. Interior of crown is coated with a thin layer of cement.**
 - c. Dry the preparation with light air pressure or with a dry gauze.**
 - d. Crown is fully seated on preparation and held in place by a cotton roll between maxillary and mandibular incisors until cement is set.**

- 16. Clean and dry the crown and the adjacent teeth.**

 - a. Restored tooth and surrounding area are free of excess cement and are clean and dry.**

- 17. Final check of occlusion and margin.**

 - a. Occlusion of the restored tooth replicates that of the unprepared tooth.**
 - b. Crown margin is sealed.**

Module 4

Placing a custom plastic temporary crown

MODULE 4

PLACING A CUSTOM RESIN TEMPORARY CROWN

This particular crown can be fabricated for a posterior or anterior tooth. A custom resin crown can be made for a full coverage, $\frac{3}{4}$ crown, inlay or onlay preparation without a great deal of involvement. It has a superior occlusal and gingival fit because it is molded from an impression of the patient's tooth. The crown's tooth-like appearance is an additional advantage. The crown's tooth-like appearance is an additional advantage. Construction of this crown may take longer to learn initially; once the contouring technique is mastered, it can be quick and easy.

In this module the fabrication of a custom resin crown for tooth #14, the maxillary left first molar, is presented.

Overview of Procedure

The procedure begins and ends with checking occlusion. After checking occlusion, the operator will need to take an alginate impression before the tooth is prepared. Check the impression for air bubbles or voids in the area of the tooth that will be prepared for the crown.

After the tooth is prepared, the operator may want to remove proximal tags from the impression and reseat the impression to check for proper placement over the prepared tooth. An acrylic resin is then mixed and placed in the alginate over the impression of the tooth that has been prepared for a crown. The impression, which is filled with acrylic, is then placed over the prepared tooth. As the acrylic resin polymerizes over the prepared tooth, it will replicate the contour of the unprepared tooth. The temporary crown is then gently eased out of the impression and ready for trimming and contouring to fit the finish line of the prepared tooth. Once the contacts and occlusion are established, the crown is polished and cemented in place.

ARMAMENTARIUM

1. PPE
2. articulating paper and holder
3. typodont with prepared tooth
4. assorted quadrant impression trays
5. tray adhesive (for plastic trays)
6. utility wax
7. alginate
8. alginate scoop
9. alginate-mixing spatula
10. plastic mixing bowl
11. lab knife (or scalpel)
12. cement mixing spatula
13. spatula (#7)
14. gauze sponges
15. acrylic resin
16. medicine dropper
17. dappen dishes
18. small scissors (or curved crown and bridge scissors)
19. spoon excavator
20. sharp soft pencil (#1) (optional)
21. acrylic bur
22. pumice impregnated rubber wheel
23. assorted discs/mandrel (Moore's)
24. petroleum jelly
25. dental mirror
26. explorer
27. dental floss
28. cotton rolls
29. temporary-cement kit
30. mixing pad
31. double-ended plastic instrument
32. lathe (optional)
33. rag wheel (optional)
34. fine polishing agents (optional)
35. low speed straight and contra angle handpiece

PROCEDURE

Preliminary Procedure

To prepare for the fabrication of an acrylic resin temporary crown, first clean the left maxillary quadrant.

1. Check to be sure you have all the supplies listed in the Armamentarium.
2. Check occlusion with the unprepared tooth #14 by placing blue articulating paper between the left maxillary and the left mandibular arches, and gently tapping the teeth together in centric occlusion. There must be at least one occlusal mark on each tooth. (Note: this pattern must be replicated when the temporary crown is placed.)
3. Take an impression of the maxillary arch before the tooth is prepared for a crown.
4. Place the prepared tooth #14 in the dentoform; retain the unprepared tooth with its occlusal markings for future reference.

Crown Fabrication and Placement Procedures

1. TAKE AN ALGINATE IMPRESSION OF THE UNPREPARED TOOTH.

Select proper try size. A sectional tray works best since the temporary crown will be constructed for a single tooth and there is no need to use a full arch tray. There are two types of sectional trays. One type is hard plastic or metal tray held in place by the operator while the alginate sets. The other type is a disposable bite tray, which is held in place by the patient occluding on it until the alginate sets.

Mix the alginate according to manufacturer's instructions. Inspect the impression to be sure all details of the prepared tooth are accurately replicated and the impression is free of large voids and torn areas or potential undercut bulges. If the impression is acceptable, use a lab knife (or scalpel) to trim large overhangs of alginate that extend beyond the impression tray and thus might cause distortion. Remove interproximal tags from the alginate impression with a sharp instrument or cotton pliers. This allows the impression to be reinserted more easily and gives sufficient bulk to the temporary. Use the air and water spray to clean the impression. Wrap with a moist paper towel until ready for acrylic resin.

Criteria

- a. Impression shows all details of the prepared tooth.
- b. Impression is free of large voids, torn areas, and defects.
- c. Impression is free of interproximal tags of alginate.
- d. Impression is clean and wrapped in moist paper towel.

2. PLACE PREPARED TOOTH IN DENTOFORM

After placing the tooth in the dentoform, reseat the impression to check for proper placement over the prepared tooth. Coat the preparation and adjacent tissue with petroleum jelly.

3. FABRICATE THE ACRYLIC RESIN CROWN.

The technique for mixing the acrylic resin can be done directly in the alginate impression or it may be mixed in a dappen dish and applied to the impression mold of the area to be temporized. In order to add directly to the impression, isolate with cotton pellets, then begin by adding a small amount of polymer then a few drops monomer (liquid) with an eye dropper directly in the impression mold of the unprepared tooth. (Let the drops fall on the walls of the preparation in order to prevent bubbles.) Then add sufficient polymer (powder) to absorb the liquid. Each ingredient is added repeatedly in turn until the tooth mold is approximately two-thirds full.

In order to use the dappen dish technique, partially fill the dappen dish with the monomer and then the polymer to absorb the liquid. The operator can add polymer gradually while tapping the dappen dish on the counter top to help saturate the monomer and eliminate air bubbles which could weaken the mix.

Regardless of which technique is used to mix the resin, the key elements are to apply the monomer and polymer repeatedly and to keep the eye dropper of monomer from touching the mix plus, taking further caution not to over fill the impression should help you form a solid crown which is not full of bubbles.

The resin in the impression is ready to be placed over the prepared tooth when it has lost its highlights and surface shine. Hot water can hasten polymerization. With even pressure, hold the impression in place or have the patient occlude; if using the disposable bite tray. The operator can hold excess acrylic resin between the fingers in order to monitor polymerization. The impression tray should be held very still until polymerization occurs (approximately 3-5 minutes). The acrylic resin will be slightly rubbery when it is ready to be removed.

Criteria

- a. Acrylic resin is mixed to proper consistency.
- b. Impression of tooth is two-thirds full of acrylic resin mix.
- c. Impression is seated over prepared tooth and held still for approximately 3-5 minutes.
- d. Acrylic is at the slightly rubbery stage when removed.

4. REMOVE CROW FROM IMPRESSION AND EXAMINE IT

Remove the crown from the impression. Use very gentle movement if the crown remains on the tooth when the impression is removed. The operator can ease the crown off of the preparation. Move very quickly at this point to trim excess bulk. Use curved crown and bridge scissors to trim away excess from the

interproximal, buccal and lingual crown margins. All of the bulk excess should be trimmed quickly to prevent final set before placing the crown on the tooth. If final set occurs before placement, the crown may shrink or warp and will not fit properly.

Inspect the crown for voids. If any voids are present, fill them with acrylic resin, using the bead-brush technique. The crown should be clean and dry before each addition of resin. Dip the brush into monomer and then into polymer; paint the mixture into the void; clean the brush in a second dish of monomer; and wipe the brush on gauze. Repeat until the void is slightly overfilled.

Criterion

- a. Crown replicates the unprepared tooth on its outer surface and the prepared tooth on its interior surface.

5. REMOVE MARGINAL EXCESS FROM CROWN.

Mark the preparation finish line with soft lead pencil. Trim the marginal excess to the finish line with acrylic bur and/or assorted discs. If the gingival 1/3 of the crown has excess bulk where the interproximal tags of the impression were trimmed, remove excess with the acrylics bur, and clean the crown of debris with an air spray.

6. CHECK CONTACTS, MARGINAL ADAPTATION, AND CONTOURS OF THE CROWN.

Place the crown on the prepared tooth, and assess its fit. If the crown does not seat completely, one or both contacts may be too bulky. Acrylic resin may be removed with the acrylic bur. Reseat the crown and check the contacts with dental floss. Should the contact areas (in the middle third) be under contoured, add acrylic resin to the crown with the bead-brush technique. The crown must be clean and dry for the resin to adhere, and it should be seated when the resin is at the rubbery stage in order to establish the contacts. Trim the acrylic resin additions with the acrylic bur, and clean away the debris with an air spray.

Once the crown is fully seated, make sure the margin meets the finish line and conforms to it. If the crown has an open margin or needs more retention, at this point you can reline the interior of the crown with resin. Reline is accomplished by mixing the resin in a dappen dish or adding monomer to the interior of the crown and slowly adding the polymer. It is important that the operator seats the crown properly and applies pressure as the acrylic polymerizes. In the clinical setting, the operator would want the patient to occlude on a cotton roll or use an index finger to assure even pressure. Acrylic additions should be smoothed with an acrylic bur or disc. A mouth mirror is used to compare the buccal and lingual contour of the crown with that of the adjacent teeth. Contour the crown as necessary. May add resin just to finish lines.

Criteria

- a. Mesial and distal contacts re-established.
- b. Crown margin is adapted to the finish line.

- c. Buccal and lingual contour of crown conforms to that of the adjacent teeth.
- d. Crown is free of debris.

7. **CHECK OCCLUSION.**

The thickness and contour of the occlusal surface of the crown depend on the pressure that was exerted during polymerization. Check occlusion after seating the crown on the prepared tooth. Compare the markings on the crown with those of the unprepared tooth. Remove any prematurities with the acrylic bur.

If the crown is in infra-occlusion, add acrylic resin, using the bead-brush technique. After applying the acrylic resin, wait a moment for the acrylic resin to develop a doughy texture; then seat the crown and close the teeth into occlusion to contour the occlusal surface of the crown.

Criterion

- a. Crown's occlusion replicated that of the unprepared tooth.

8. **SMOOTH AND POLISH THE CROWN.**

Remove the crown. With a straight handpiece and a pumice-impregnated rubber wheel, smooth all of its surfaces. Use light, intermittent strokes to keep from deforming the contours and contacts. For a highly polished surface, you may use a polishing agent with the rag wheel on a lathe.

Criterion

- a. Crown is smooth and shiny.

9. **CHECK CROWN BEFORE CEMENTATION.**

Reseat the crown. Check its marginal adaptation, contacts, contours, and occlusion, as before.

Criteria

- a. Crown marginal meets, contours to, and fits snugly against preparation finish line.
- b. Crown contacts adjacent teeth.
- c. Crown's contours duplicate those of unprepared tooth #14.
- d. Crown's occlusion replicates the occlusion of unprepared tooth #14.

10. **CEMENT THE CROWN.**

Remove the crown; rinse and dry the preparation area. Isolate the area with rolls of cotton. Apply a thin layer of petroleum jelly to the exterior of the

crown, to facilitate the removal of the excess cement. The lubricant should not contact the interior of the crown; it will prevent adherence.

Mix temporary cement according to the manufacturer's directions. When it has a uniform consistency and flows freely, use a plastic instrument to coat the internal surfaces of the crown with a thin layer of the cement.

Seat the crown on the preparation. Place a cotton roll on the occlusal surface of the crown, and occlude the teeth. Check with the explorer at the crown's margin to see that the crown is fully seated. Hold the teeth in occlusion until the explorer can no longer penetrate the extruded cement.

When the cement is set, remove the cotton rolls, and use the explorer to chip away any excess cement. Use dental floss to free the interproximal areas of cement. A knot can be tied in the floss to aid in interproximal removal of cement. Rinse and air dry the restoration.

Criteria

- a. Preparation is clean, dry and isolated.
- b. The exterior of the crown is lubricated.
- c. The interior of the crown is coated with a thin layer of temporary cement.
- d. Crown's margin fits snugly at preparation finish line when crown is seated.
- e. No excess cement is present.
- f. Restoration is clean and dry.

11. CHECK CROWN AFTER CEMENTATION.

Using the mirror and the explorer, check the crown margin for fit and seat. At least 95% of the margin must meet the finish line. Compare the contours of the crown with those of the adjacent teeth.

Check contacts, and make a final occlusal check. Should the crown need re-contouring, use a green stone and then a fine disc.

Criteria

- a. At least 95% of the crown margin meets preparation finish line, and entire margin is sealed with cement.
- b. Crown contours are aligned with those of adjacent teeth.
- c. Crown contacts adjacent teeth mesially and distally.
- d. Crown's occlusion matches occlusion of unprepared tooth

SUMMARY OF PROCEDURE AND CRITERIA

| <u>Procedures</u> | <u>Criteria</u> |
|--|--|
| 1. Take an alginate impression of the unprepared tooth | a. Impression shows all of the details of the prepared tooth. |
| | a. Impression shows all of the details of the unprepared tooth. |
| | b. Impression is free of large voids, torn areas, and defects. |
| | c. Impression is free of interproximal tags and large overhangs of alginate. |
| 2. Test seating the alginate impression on dentoform. | d. Impression is clean and free of excess water. |
| | a. The impression of the prepared tooth seats fully into the dentoform of the unprepared tooth. Coat prep and tissue with petroleum jelly. |
| 3. Fabricate the acrylic resin crown. | a. Impression of tooth #14 is two-thirds full of acrylic resin mix. |
| | b. Impression is fully seated on the dentoform with even pressure. |
| | c. Impression is held very still (approximately 3-5 minutes) until slightly rubbery. |
| 4. Remove crown from impression and examine it. | a. Crown replicates the unprepared tooth on its outer surfaces and the prepared tooth on its interior. |
| 5. Remove marginal excess from crown. | a. Crown is trimmed to the impression margin. |
| 6. Check contacts, marginal adaptation, and contours of the crown. | b. Crown is free of debris. |
| | a. Mesial and distal contacts re-established. |
| | b. Crown margin is adapted to the finish line. |
| | c. Buccal and lingual contour of crown conforms to that of the adjacent teeth. |

- d. **Crown is free of debris.**
- 7. **Check occlusion.**
 - a. **Crown's occlusion replicates that of the unprepared tooth.**
- 8. **Smooth and polish crown.**
 - a. **Crown is smooth and shiny**
- 9. **Check crown before cementation.**
 - a. **Crown margin meets, contours to, and fits snugly against preparation finish line.**
 - b. **Crown contacts adjacent teeth.**
 - c. **Crown contours replicate those of unprepared tooth #14.**
 - d. **Crown occlusion replicates that of unprepared tooth #14.**
- 10. **Cement the crown.**
 - a. **Preparation is clean, dry and isolated.**
 - b. **The exterior of the crown is lubricated.**
 - c. **The interior of the crown is coated with a thin layer of temporary cement.**
 - d. **Crown margin fits snugly at preparation finish line when crown is seated.**
 - e. **No excess cement is present.**
 - f. **Restoration is clean and dry.**
- 11. **Check crown after cementation.**
 - a. **At least 95% of the crown margin meets preparation finish line, and entire margin is sealed with cement.**
 - b. **Crown contours are aligned with those adjacent teeth.**
 - c. **Crown contacts adjacent teeth mesially and distally.**
 - d. **Crown occlusion matches the occlusion of the unprepared tooth.**

Module 5
**Additional techniques employed for fabrication of
custom temporary crowns**

MODULE 5
ADDITIONAL TECHNIQUES EMPLOYED FOR FABRICATION OF CUSTOM TEMPORARY CROWNS

The previous modules have listed the basic objectives and described the technique for fabrication of a custom acrylic temporary crown. There are a few other techniques that are employed in some dental practices. This segment of the temporary crown module is intended to familiarize the student with these techniques: however, actual practice is recommended prior to attempting them in the clinical setting.

Additional techniques for fabrication of custom temporary crowns which will be discussed include the following:

1. Wax molding technique
2. Silicone putty impression
3. Intraoral molding technique
4. Vacuum-formed plastic resin tray
5. Temp tab impression
6. Relining of the aluminum temporary crown

Wax Molding Technique

Instead of taking an alginate impression, the operator may use pink baseplate wax for taking the impression.

1. Cut a piece of 3" x 5" baseplate wax to approximately 3" x 2 ½" and fold it in half lengthwise. Place the wax in a bowl of hot water to soften. (or place over hot water facet or flame.
2. Place the wax over the prepared tooth and finger burnish it onto the occlusal surface and into the interproximal areas. Wax is hardened by cooling with air from air/water syringe. Once the wax matrix hardens, remove it from the prepared tooth and trim excess wax.
3. Use the wax molded impression in the same manner as an alginate impression. The operator may want to cool the acrylic resin while it is polymerizing with the air from the air/water syringe.

Some operators prefer the wax molding technique because it is less expensive than alginate impressions and trays and it saves time.

Silicone Putty Impression

Another impression material used for custom temporary crowns is silicone putty. Silicone putty is placed in a sectional tray like the alginate impression material. Some operators prefer silicone putty impressions because of their versatility for use in a broad range of techniques. Most manufacturers supply additional curing silicones in various viscosities. The advantage with the silicone putty is that the final impression is taken with the putty impression serving as your custom tray.

Temp Tab Impressions

Temp Tabs are a small disk of plastic used to make a matrix of the unprepared tooth. Although they are somewhat expensive, they are simple to use and can be reused as needed.

1. The Temp Tab is heated in hot water until clear.
2. The Tab is molded over the unprepared tooth and allowed to set.
3. Air may hasten the cooling and set of the Tab.
4. The prepared tooth, adjacent tissue, and Temp Tab with petroleum jelly.
5. Add acrylic to Tab and seat over prepared tooth.

Intraoral Molding Technique

An impression of the tooth is not necessary when the intraoral molding technique or “blob” technique is employed. The acrylic resin itself is used to fabricate the temporary crown without any preliminary impression prior to tooth preparation.

1. Mix the acrylic resin in a dappen dish as described previously.
2. When the resin has lost its highlights and has a doughy consistency (like putty), the operator molds the resin into a rectangular “blob”.
3. The acrylic is molded over the prepared tooth and the patient occludes in order to establish the impression.
4. Gross excess will be present on the buccal, lingual and interproximal surfaces. The excess is trimmed in the mouth with a sharp instrument, or the temporary is removed from the mouth and crown and bridge scissors are used for trimming. It is important to proceed quickly at this point to prevent shrinkage. The final polymerization should be done in the mouth. The patient’s tongue can help mold the resin on the lingual surface.
5. Proceed with trimming and contouring according to dental anatomy of the particular tooth being restored. Check the occlusion.
6. Sometimes it is necessary to re-line the first attempt or to add contact areas of the occlusal surface. This re-lining is easily accomplished as described in Module 3 and 4.

The advantage of this technique is that it does not require any initial work before the tooth is prepared. It is preferred by some operators when the patient has broken teeth and a preliminary impression of the unprepared tooth is impossible. The intraoral molding technique works well for anterior or posterior teeth. It also has excellent margin adaptation. This technique is particularly suitable for inlays, onlays and $\frac{3}{4}$ crowns.

Vacuum-formed Plastic Resin Tray

A vacuum-formed plastic resin tray is a plastic matrix heated to the shape of the arch using a vacuum forming system. It can be a full arch matrix or a sectional. It is used when the dentist is making multiple crowns of several unit bridges. In this case, it is very helpful to have a clear plastic resin sheet vacuum-formed to the study model.

This type of tray enables the operator to have a custom tray made to fit the patient's mouth without the distortion that can occur with an alginate impression. This custom form can be re-used a number of times if needed, unlike alginate impressions. The disadvantage of the plastic resin tray technique is that it may require two appointments: one for the study models used to make the tray and one for the crown preparation. The advantage is the clear tray allows the operator to see if it is seated properly.

Relining Aluminum Shell Crowns

At times, aluminum shell crowns may not have adequate retention or marginal adaptation. It is possible to reline the shell with acrylic resin. This technique would result in an aluminum temporary crown which fits better and last longer.

1. Coat prepared tooth with petroleum jelly.
2. Mix acrylic in dappen dish or directly in the aluminum shell.
3. Place acrylic in the aluminum shell, 2/3 full, and allow time for surface to dull.
4. Place lined shell on prepared tooth and apply even pressure, or have the patient bite down.
5. Trim excess acrylic in the mouth with a sharp instrument.
6. Smooth, polish, and clean crown before cementing.

STUDY QUESTIONS-MODULE 1

1. Why are temporary crowns placed?
2. List the types of temporary crown.
3. What is a finish line?
4. What are the common forms of finish lines?
5. List the major types of resin materials. Give their advantages and disadvantages.
6. Why is it vital that the liquid of the acrylic resin be thoroughly mixed with the powder?
7. Define occlusion and centric occlusion.
8. Why is it important to for temporary crowns maintain stable occlusion?
9. What causes unstable occlusion?
10. During cementation. Why is it imperative not to desiccate the preparation?
11. Why is it important to practice proper asepsis?
12. What function does the temporary cement serve other than adhering the crown to the preparation?
13. Why is it important that the margin fit well?

STUDY QUESTIONS-MODULE 2

1. List the advantages and disadvantages of temporary aluminum crowns.
2. What measurement is used first in determining which size crown to use?
3. If the aluminum temporary is short what should be done?
4. What adjustments should be made if the crown is in supra-occlusion? Infra-occlusion?
5. What criteria determine a properly fit temporary aluminum crown?

STUDY QUESTIONS- MODULE 3

1. What techniques are used to adjust the size of a temporary polycarbonate crown at the try in step?
2. What indicates that a temporary crown is over-contoured on the lingual? On the facial?
3. Why must the crown be removed from the preparation before the acrylic is completely polymerized?
4. What difference would it make if the crown were over-contoured at the gingival third?
5. What difference would it make if the incisors were not in occlusion at the preparation check, but they were after the crown was cemented in place?
6. What is the function of the acrylic resin liner?
7. Why is the prep and adjacent tissue coated with petroleum jelly?

STUDY QUESTIONS-MODULE 4

1. What are the advantages and disadvantages of custom temporary crown?
2. How can you hasten polymerization?
3. When is the resin ready to place over the prepared tooth?
4. What can cause distortion of the occlusion and contours of a custom crown during polymerization?
5. When can you remove the impression with the acrylic from the prepared tooth?
6. List the criteria for the cemented crown.

STUDY QUESTIONS-MODULE 5

1. What are the alternative techniques for fabrication of a custom temporary crown?
2. What are the advantages of each technique?
3. Which technique is considered most versatile? Affordable?
4. Why is it necessary for the operator to reline the aluminum shell if it already fits snugly to the finish line?

REFERENCES

- Baum, Lloyd, McCoy, Richard B. Advanced Restorative Dentistry. Philadelphia: W.B. Saunders Co., 1984
- Castano, Frances, A., Alden, Betsy. Handbook of Expanded Dental Auxiliary Practice. J.B. Lippincott Co., 1973.
- Chasteen, Joseph E. Essentials of Clinical Dental Assisting. The C.V. Mosby Co., 1989.
- Phillips, William J. Elements of Dental Materials. Philadelphia: W.B. Saunders Co., 1984.
- Simon, William J. Clinical Dental Assisting. Harper and Row, Inc., 1973.
- Spohn, Eric E., Halowski, Wendy A., and Berry, Thomas G. Operative Dentistry Procedures for Dental Auxiliaries. The C. V. Mosby Co., 1981.

